Accepted Preprint

The argument for aggressive coiling of aortopulmonary collaterals in single ventricle patients.

Herbert J Stern MD, FACC, FSCAI

Editorial:

Aortopulmonary collaterals (APCs) are present in up to 80% [1, 2, 3, 4] of single ventricle patients undergoing pre-Fontan catheterization. It has been theorized that hypoxia is a potent stimulus for their development [5]. There is generally no consensus as to their impact in the mid-long term course of single ventricle patients. Bradley et al. argued that their presence in the immediate post-operative period following Fontan repair had no impact on duration of pleural effusions or resource utilization in terms of length of mechanical ventilation, ICU stay or hospital stay [6], prompting many centers to ignore these vessels at the time of their pre-Fontan heart catheterization. While their findings were counter-intuitive, even to the authors, this single study has been used as justification to ignore aortopulmonary collaterals not only at the pre-Fontan catheterization but long-term in a number of centers [informal polling and personal communication]. In those centers performing catheter occlusion of APCs, the criteria for occlusion is subjective or based on hemodynamic data which has not been validated in terms of defining what is significant APC flow. MRI assessment of pulmonary artery and pulmonary vein flow using phase contrast velocity mapping [7] is a promising and accurate modality for calculating APC flow but is expensive, time consuming and usually requires general anesthesia. Finally, the long-term impact of permanently occluding vessels off the subclavian arteries and thoracic descending aorta is unknown. Given this backdrop, what is an interventionalist to do when he/she encounters APCs during the pre-Fontan catheterization?!

It is well known that chronic volume loading raises filling pressures, induces adverse remodeling, triggers apoptosis and activates neurohormones all of which conspire to cause progressive ventricular dysfunction. This pathophysiologic cascade has been well-described in the adult literature [8, 9] and there is compelling data to suggest that these same mechanisms apply to the single ventricle patient [10, 11, 12]. Additionally, Ascuitto et al., demonstrated that competitive flow and pressure elevation from APCs can lead to dramatic energy losses resulting in elevated filling pressures and decreased cardiac index in a hydrodynamic model further implicating APCs as pathologic entities [13].

Confusing matters further, the anatomy of APCs has been poorly described in the literature and therefore the techniques to effectively occlude these vessels have been sub-optimal. It is critically important to understand that arteries arising from the subclavian arteries (including the internal mammary arteries, thyrocervical trunk, lateral thoracic branches, etc.) and intercostal arteries normally have extensive connections between them (Figure1). Occluding only the origins of these vessels, which have APCs arising from them, is inadequate in occluding APC flow as distal feeder vessels will always revascularize them. The entire length of the feeder vessel, when applicable, needs to be occluded to prevent this phenomenon from occurring (Figures 2-5). This task has been

Accepted Manuscript

simplified by the availability and use of coaxial microcatheters (Tracker-Target Therapeutics, Fremont, CA; Progreat-Terumo Interv. Systems Somerset, NJ-) and platinum microcoils (Micronester, Cook Inc.-Bloomington, IN; Target platinum coils, Target Therapeutics -Fremont, CA).

While methods to calculate APC flow need to be refined so that potentially important branches off the aorta are not occluded, we believe that the presence of APCs in single ventricle patients is detrimental to optimal ventricular function. Until those methods are developed, parameters including oxygen step-up and pressure elevation in the pulmonary arteries, upper lobe filling defects suggesting competitive flow (Figure 6), elevated ventricular end diastolic pressures, size of APCs, density of pulmonary capillary blush and pulmonary venous return (Figure 7) should all be considered when deciding to occlude these vessels. There is a disturbing trend towards gradual attrition in single ventricle patients partly due to ventricular dysfunction [14]. In addition to other well-described anatomical determinants for long-term survival [15], attention to elimination of APC flow is important and often overlooked. Using the rationale that early Glenn shunting (around 4 months) is preferred to unload the single ventricle and prevent deleterious long-term consequences [16], aggressive coiling of APCs should be viewed in this same light. Despite our opinions however, multicenter prospective double-blind studies are needed to evaluate the impact of APCs on neurohormonal activation, volume loading, filling pressures, ventricular function and correlation with adverse consequences including protein losing enteropathy, atrial arrhythmias, pleural effusions, ascites and death.

References:

1. Ichikawa H, Yagihara T, Kishimoto H, et al. (1995) Extent of aortopulmonary collateral blood flow as a risk factor for Fontan operations. Ann Thorac Surg 59:433-437
2. Kanter KR, Vincent RN, Raviele AA. (1999) Importance of acquired systemic-to-pulmonary collaterals in the Fontan operation. Ann Thorac Surg 68:969-975
3. Spicer RL, Vzark KC, Moore JW et al. (1996) Aortopulmonary collateral vessels and prolonged pleural effusions after modified Fontan procedures. Am Heart J 131:1164-1168
4. Triedman JK, Bridges ND, Mayer JE, et al (1993) Prevalence and risk factors for aortopulmonary collateral vessels after Fontan and bidirectional Glenn procedures. J Am Coll Cardiol 22:207-215
5. Yu CH, Chen MR. (2008) Clinical Investigation of Systemic-Pulmonary Collateral Arteries. Pediatr Cardiol 29:334-338
6. Bradley SM, McCall MM, Sistino JJ, and et al. (2001) Aortopulmonary Collateral Flow in the Fontan Patient: Does It Matter? Ann Thorac Surg 72: 408-415
7. Valsangiacomo ER, Barrea C, Macgowan CK, et al. (2003) Phase-contrast MR assessment of pulmonary venous blood flow in children with surgically repaired pulmonary veins. Pediatr Radiol 33:607-613
8. Haas GJ, Leier CV. (2009) Are Hemodynamic Parameters Predictors of Mortality? Heart Failure Clin 5:229-240

Accepted Preprint

9. Yan RT, White M,Yan AT, et al. (2005) Usefulness of Temporal Changes in Neurohormones as Markers of Ventricular Remodeling and Prognosis in Patients With Left Ventricular Systolic Dysfunction and Heart Failure Receiving Either Candesartan or Enalapril or Both. Am J Cardiol 96:698-704
10. Ishibashi N, Aoki M, Watanabe M, et al. (2008) Risk Factor of Interim Failure and Early Detection of the High-Risk Patients with Functional Single Ventricle After Blalock-Taussig Shunt. J Card Surg 23;488-492
11. Lechner E, Gitter R, Mair R, et al. (2008) Aminoterminal Brain Peptide levels in Children and Adolescents After Fontan Operation Correlate with Congestive Heart Failure. Pediatr Cardiol 29:901-905
12. Piran S, Veldtman G, Siu S, et al. (2002) Heart Failure and Ventricular Dysfunction in Patients With Single or Systemic Right Ventricles. Circulation 105:1189-1194
13. Ascuitto RJ, Ross-Ascuitto NT. (2004) Systemic-to-Pulmonary Collaterals: A Source of Flow Energy Loss in Fontan Physiology. Pediatric Cardiology 25; 5:472-481
14. Khairy P, Fernandez SM, Mayer JE, et al. (2008) Long-Term Survival, Modes of Death, and Predictors of Mortality in Patients With Fontan Surgery. Circulation 117:85-92
15. Hosein RBM, Clarke AJB, McGuirk, SP, et al. (2007) Factors influencing early and late outcome following the Fontan procedure in the current era. The “Two Commandments”? Eur J Cardio-Thor Surg 31:344-353
16. Mahle WT, Wernovsky G, Bridges ND, et al. (1993) Impact of early Ventricular Unloading on Exercise Performance in Preadolescents With Single Ventricle Fontan Physiology. J Am Coll Cardiol 34:1637-1643

Accepted Manuscript

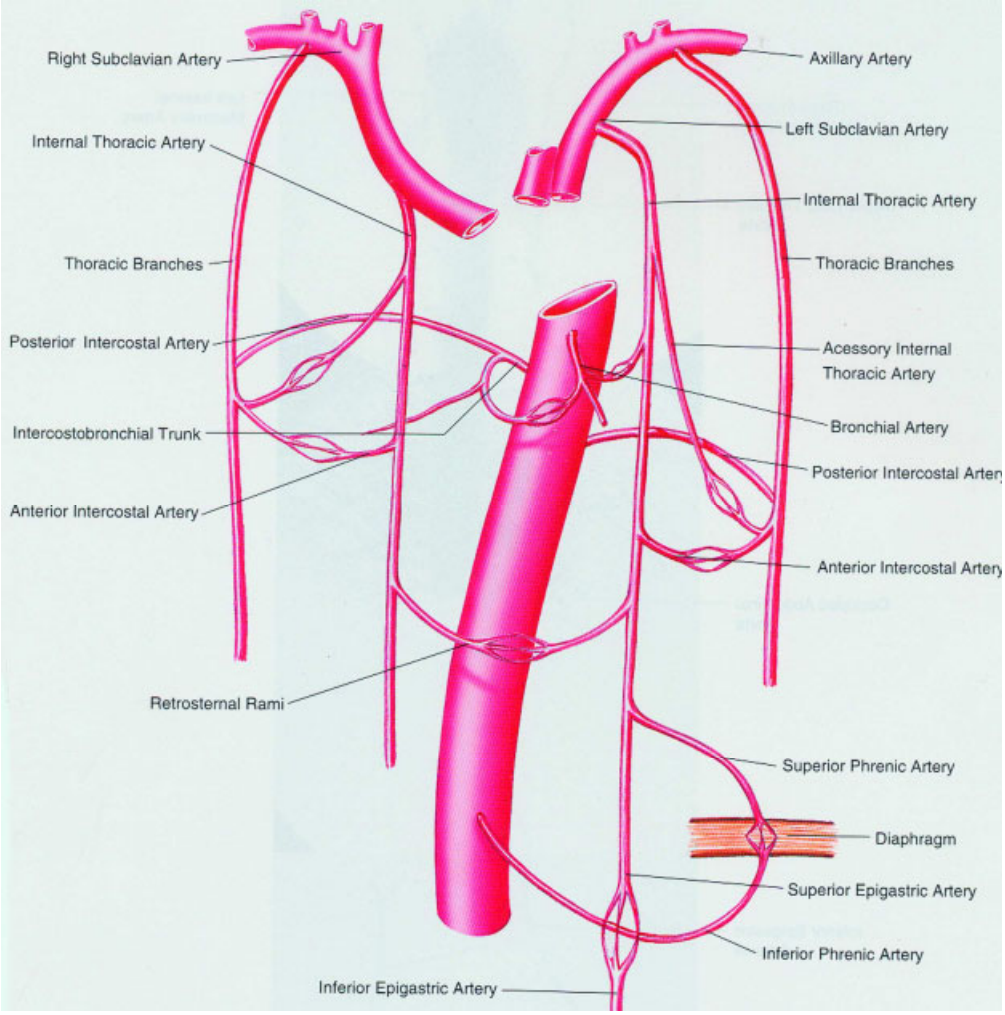

From Atlas of Vascular Anatomy (1997), Uflacker, R. Anastomotic connections of the thoracic aorta
170x172mm (300 x 300 DPI)

Accepted Manuscript

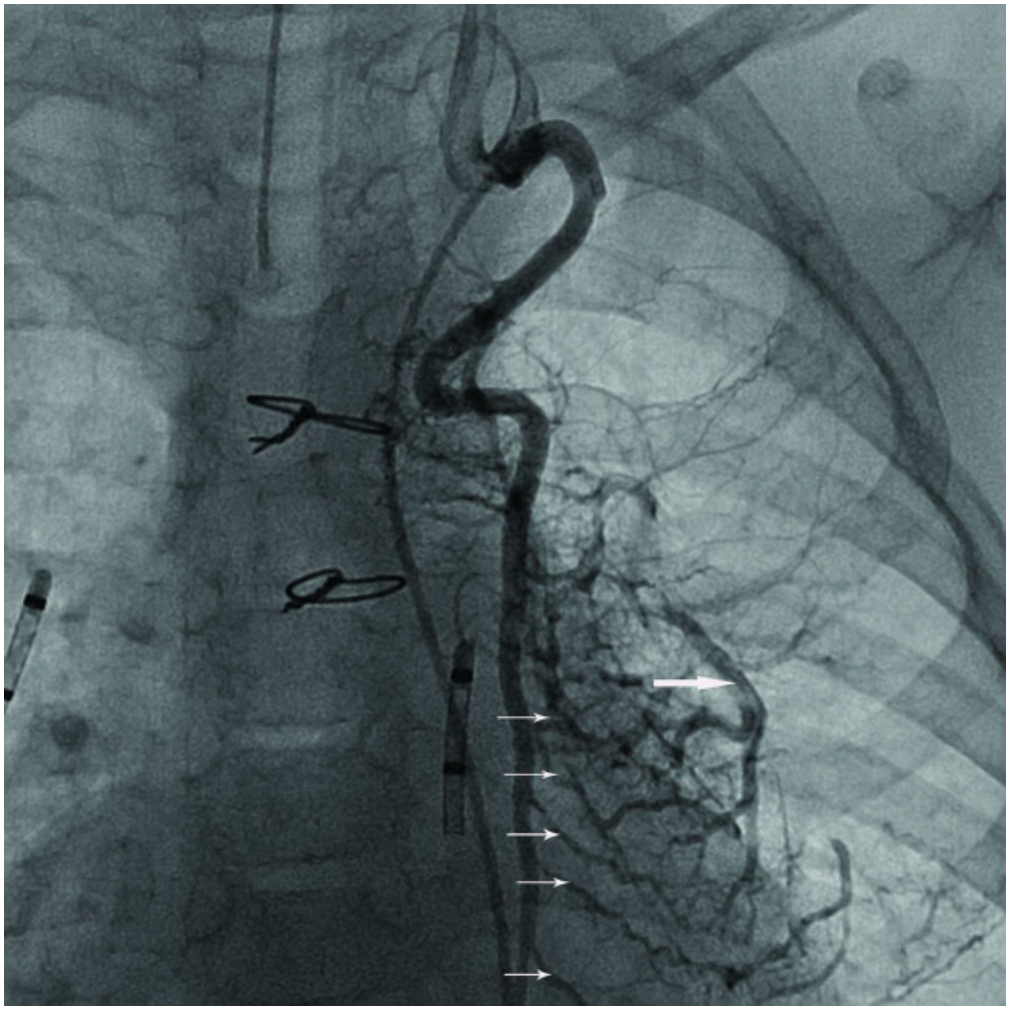

Injection in left internal mammary artery (LIMA). Small arrows depict anastomotic connections to anterior intercostal arteries supplying large amount APC flow. Notice connections along entire length of LIMA and dense filling of left pulmonary vein (large arrow).
180x180mm (300 x 300 DPI)

Accepted Manuscript

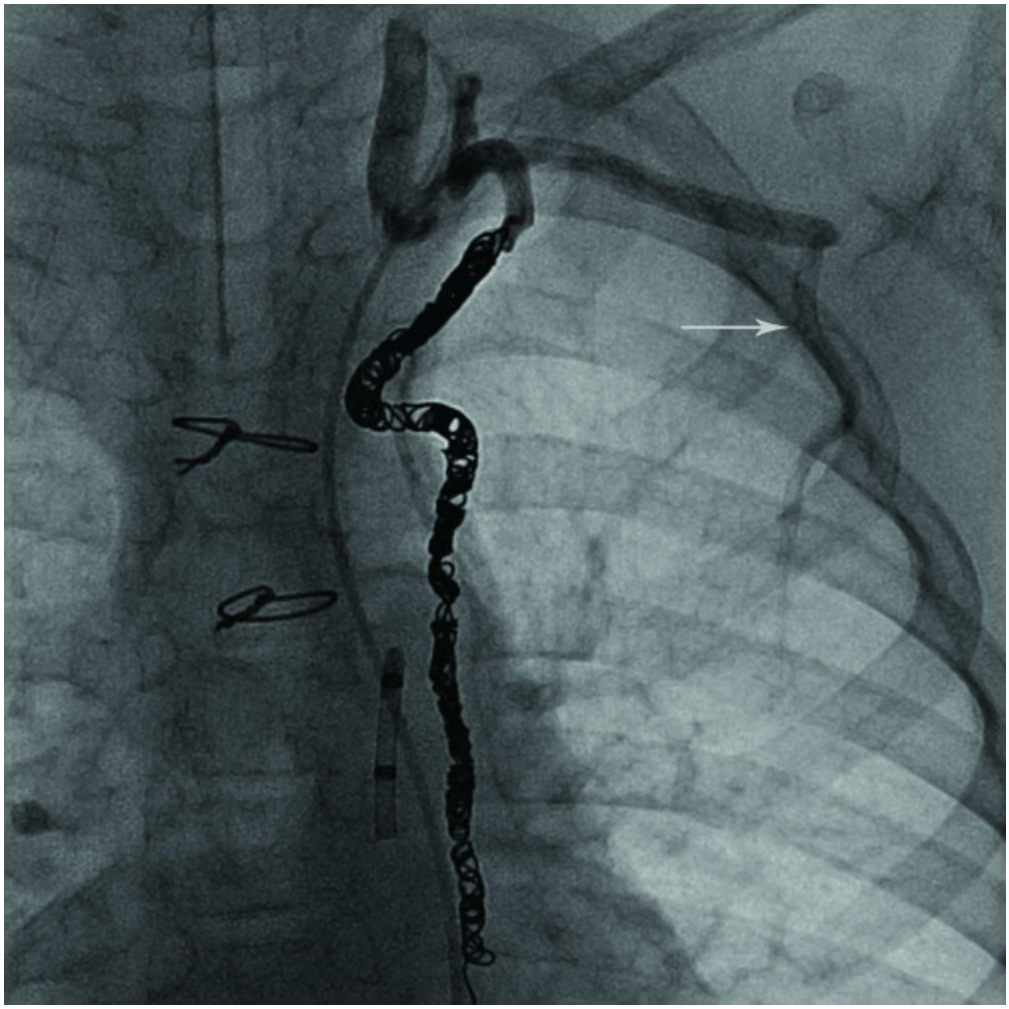

Injection in LIMA following coil occlusion using Cook Micronester coils. Arrow depicts reflux into lateral thoracic artery also supplying collateral flow.
180x180mm (300 x 300 DPI)

Accepted Manuscript

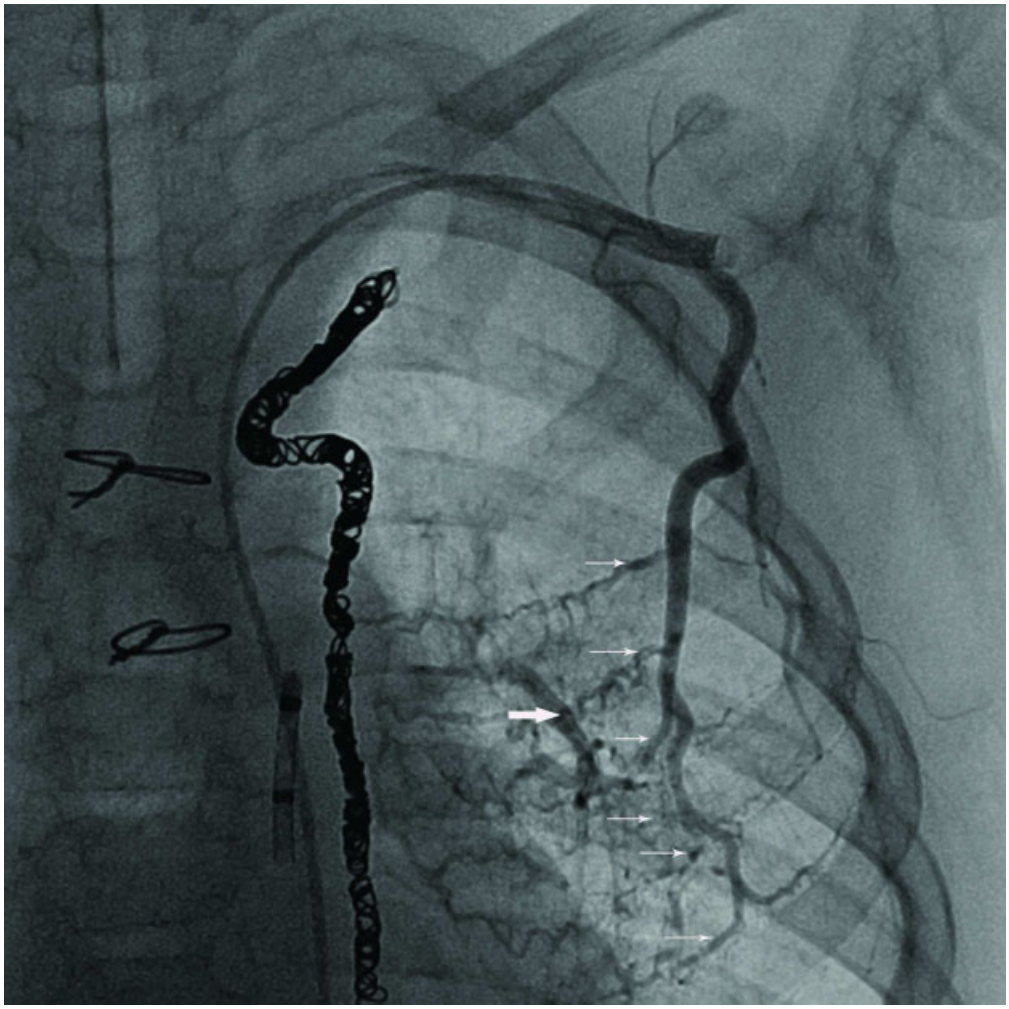

Injection in left lateral thoracic artery. Small arrows depict anastomotic connections to anterior intercostal arteries and LIMA. Large arrow depicts prompt filling of left pulmonary vein.
180x180mm (300 x 300 DPI)

Accepted Manuscript

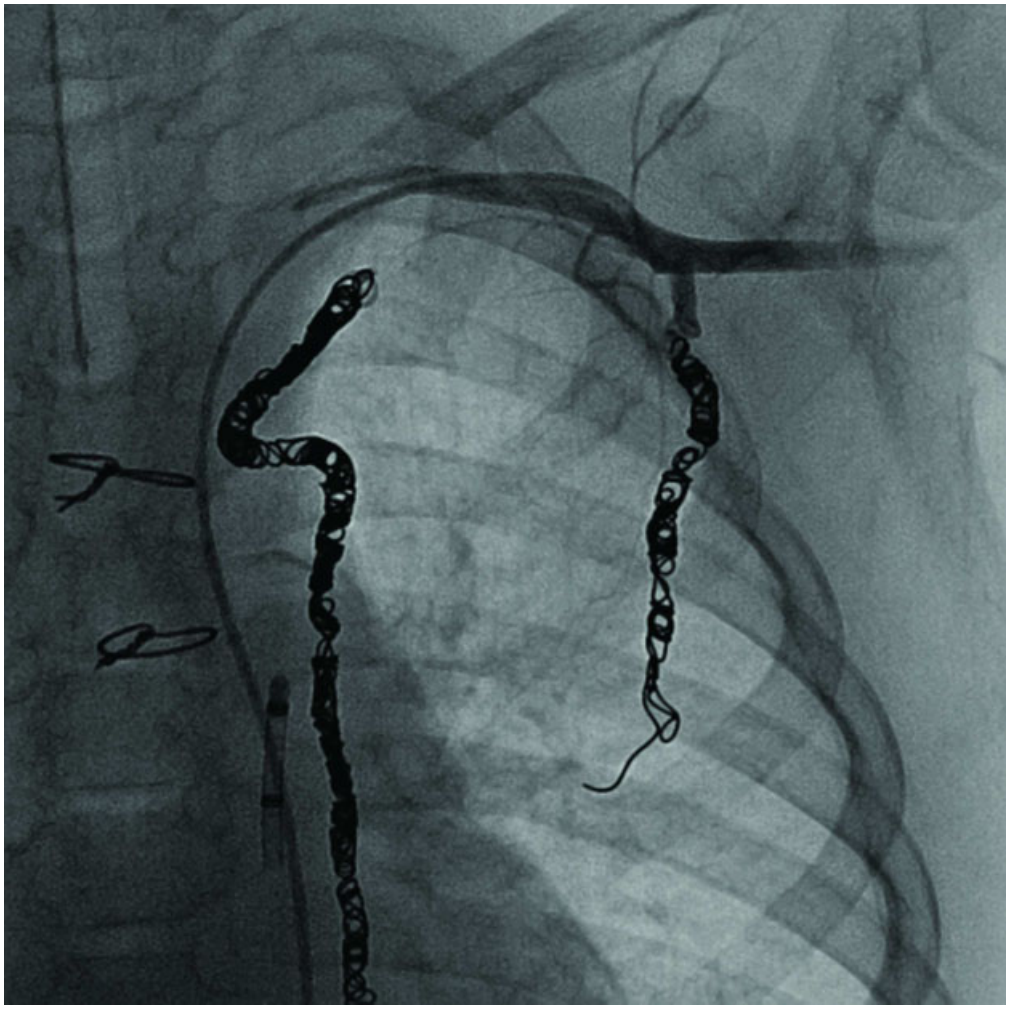

Injection in left lateral thoracic artery following coil occlusion with Cook Micronester coils of LIMA and lateral thoracic artery. No residual collateral flow seen.
180x180mm (300 x 300 DPI)

Accepted Manuscript

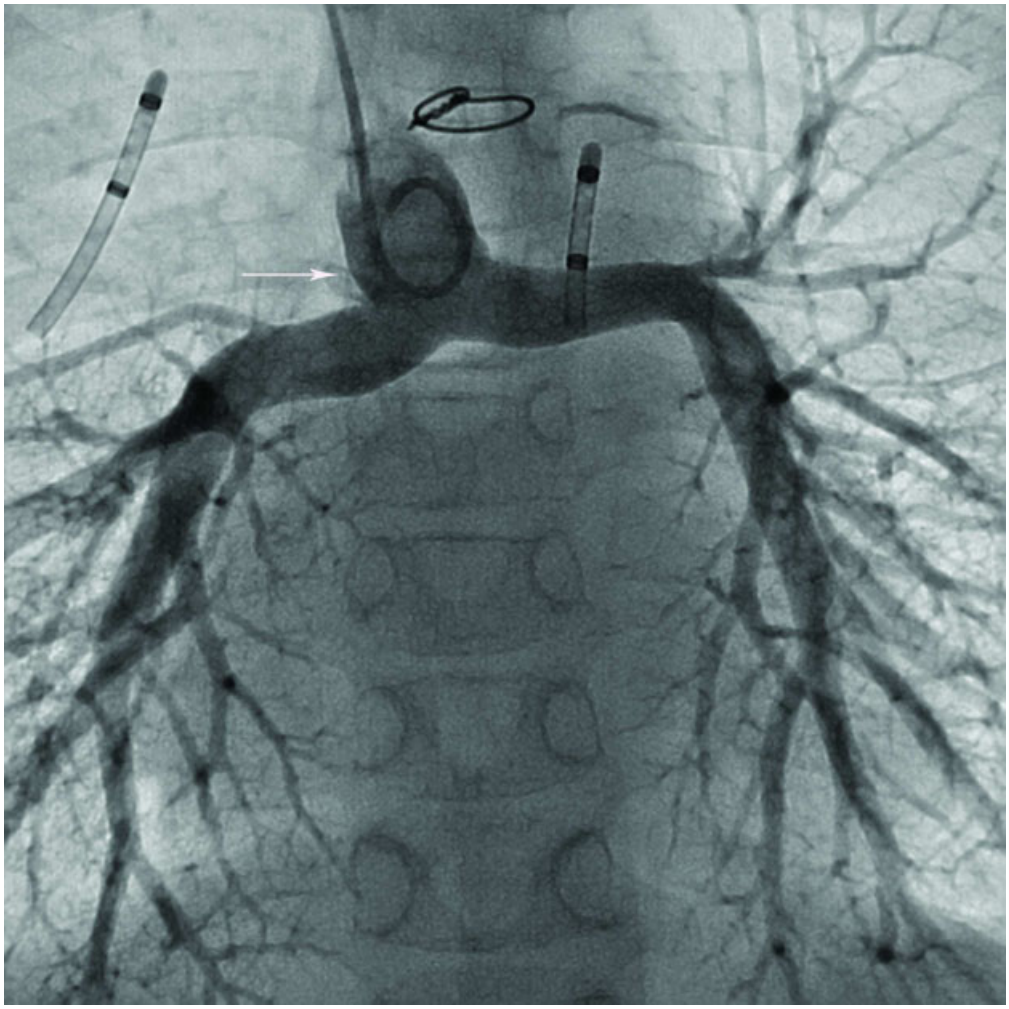

Injection in cavopulmonary shunt. Notice no flow in right upper lobe despite patent vessel due to competitive flow from APCs
180x180mm (300 x 300 DPI)

Accepted Manuscript

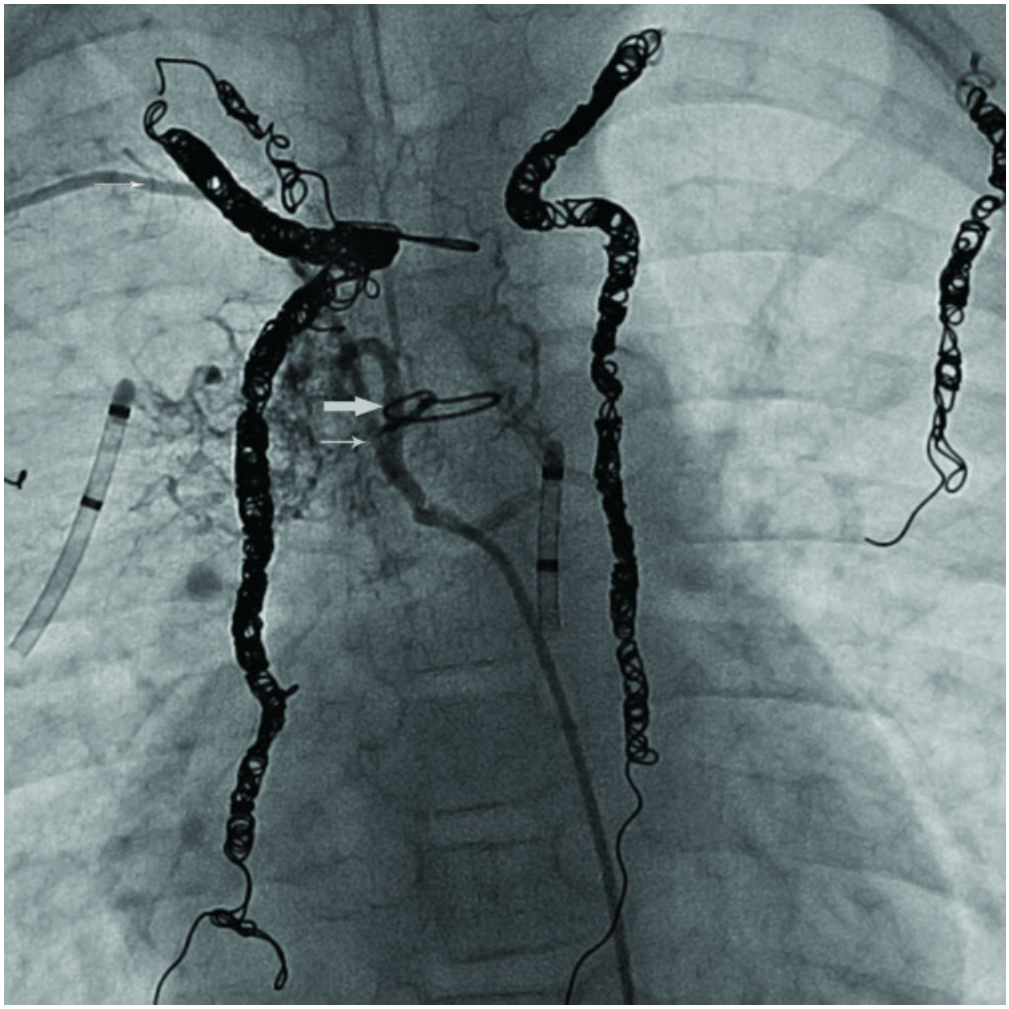

Injection in intercostal artery off thoracic aorta. Small arrows depict normal intercostal vessel. Large arrow depicts sizeable collateral supplying much APC flow.
180x180mm (300 x 300 DPI)